



Improved Low Contrast Visual Acuity and Reduction in Retinal Ganglion Cell Loss with Privoseptor in Acute Optic Neuritis: Results from a Multicenter Randomized Placebo-Controlled Double-Masked Trial

Martin Zinkernagel, MD, PhD;

Sophie Bonnin, MD, PhD; Céline Louapre, MD PhD; Louise-Laure Mariani, MD, PhD; Mikael Cohen, MD, PhD; Caroline Froment-Tilikete, MD, PhD; Mark Kupersmith, MD; Leonard A Levin, MD, PhD; Sabri Markabi MD; Caroline Papeix, MD, PhD; Valerie Touitou, MD, PhD; Sebastian Wolf, MD, PhD; Pablo Villoslada, MD, PhD

Relevant Financial Disclosures

Bayer (C,F), Janssen (C), Alcon (C,F), Roche (C), Novartis (C,I), Sandoz (C,F), Annexon (C), Abbvie (C, F), Oculis (C), Novago (C), BCN Peptides (C), Perivision (C), Priothera (C), Astellas (C), Amgen (F), Haag streit (F), Bausch and Lomb (F), Théa (F), Mediconsult (F), Oertli ophthalmologic (F), Santen (F), EURETINA (Board of directors), EU EYE (Board of directors)

Optic Neuritis, an Acute Inflammation of the Optic Nerve Which Can Lead to Permanent Visual Impairment

Orphan Disease^{1,2}

Acute inflammation of the optic nerve impacting retinal ganglion cells and leading to vision loss

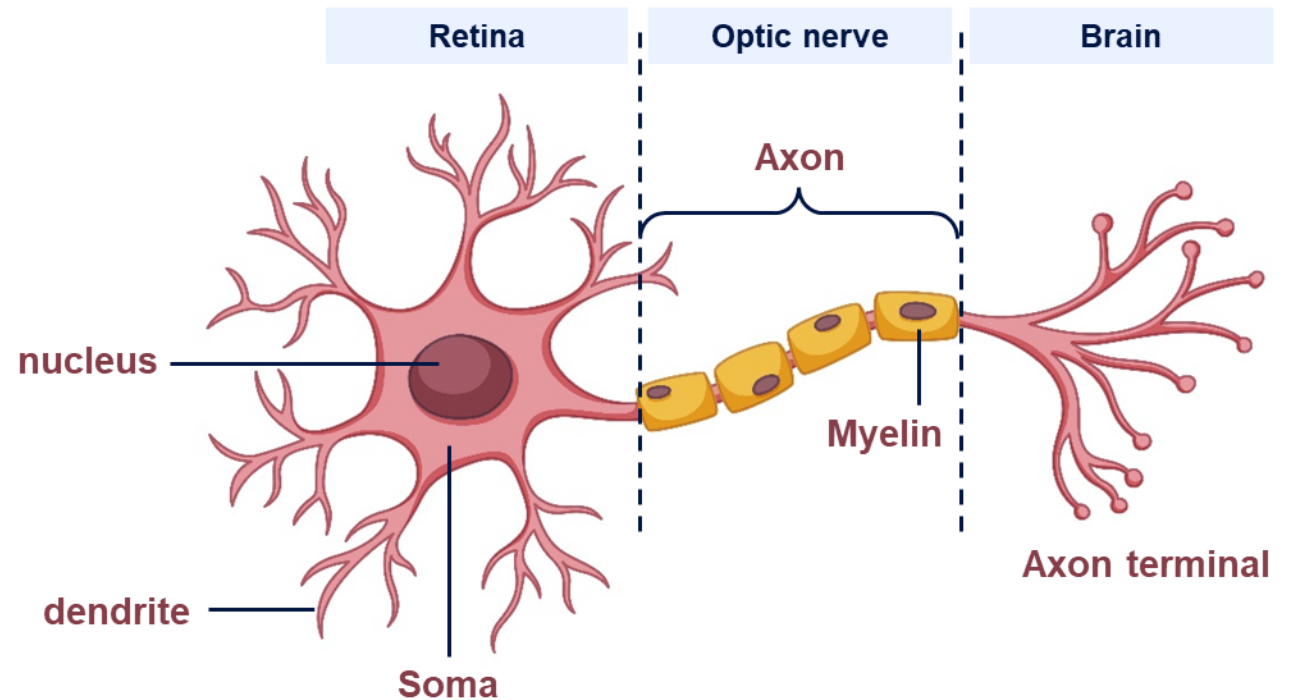
- Type of neuropathy causing vision loss and pain, and can lead to permanent visual impairment and reduced contrast sensitivity



- Mainly affecting young women with an average onset at age 32³

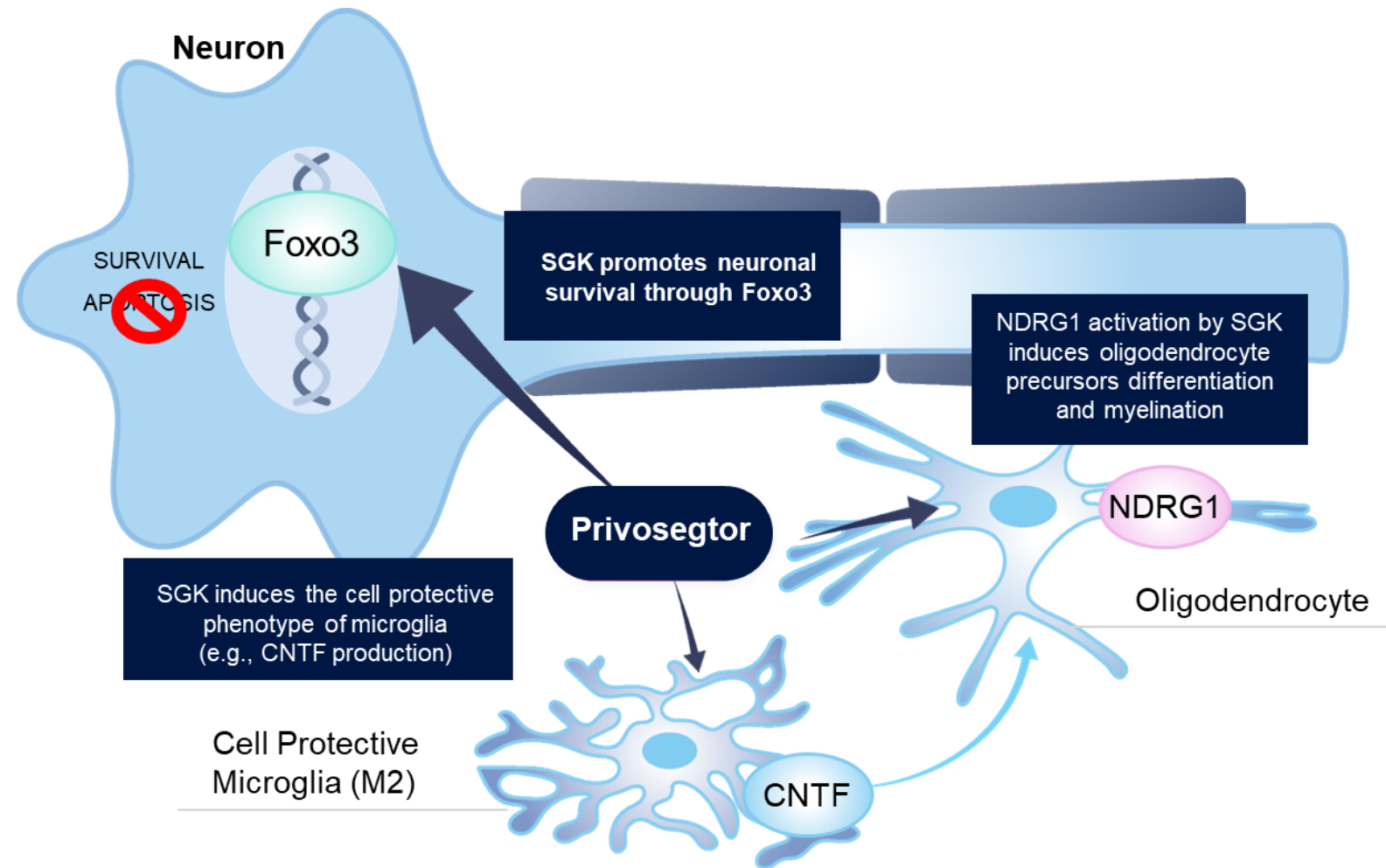
Direct link with chronic conditions like **multiple sclerosis (MS)** and other autoimmune diseases

Anatomy of a retinal ganglion cell

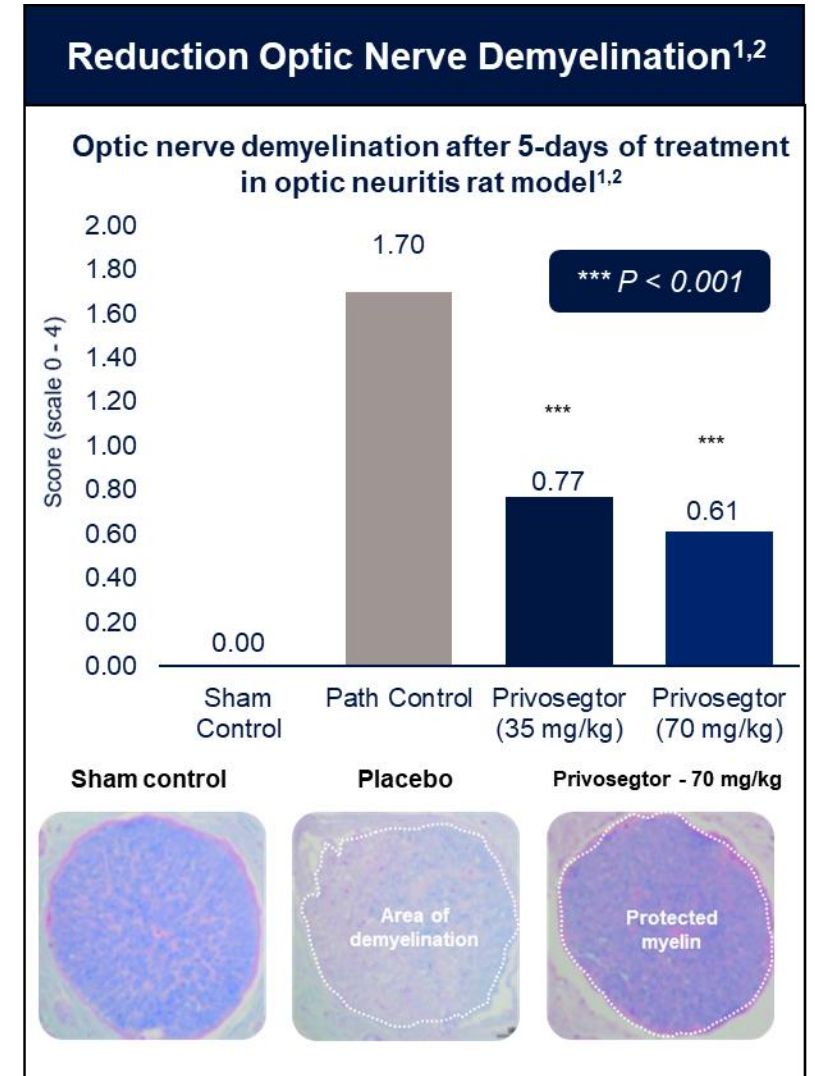
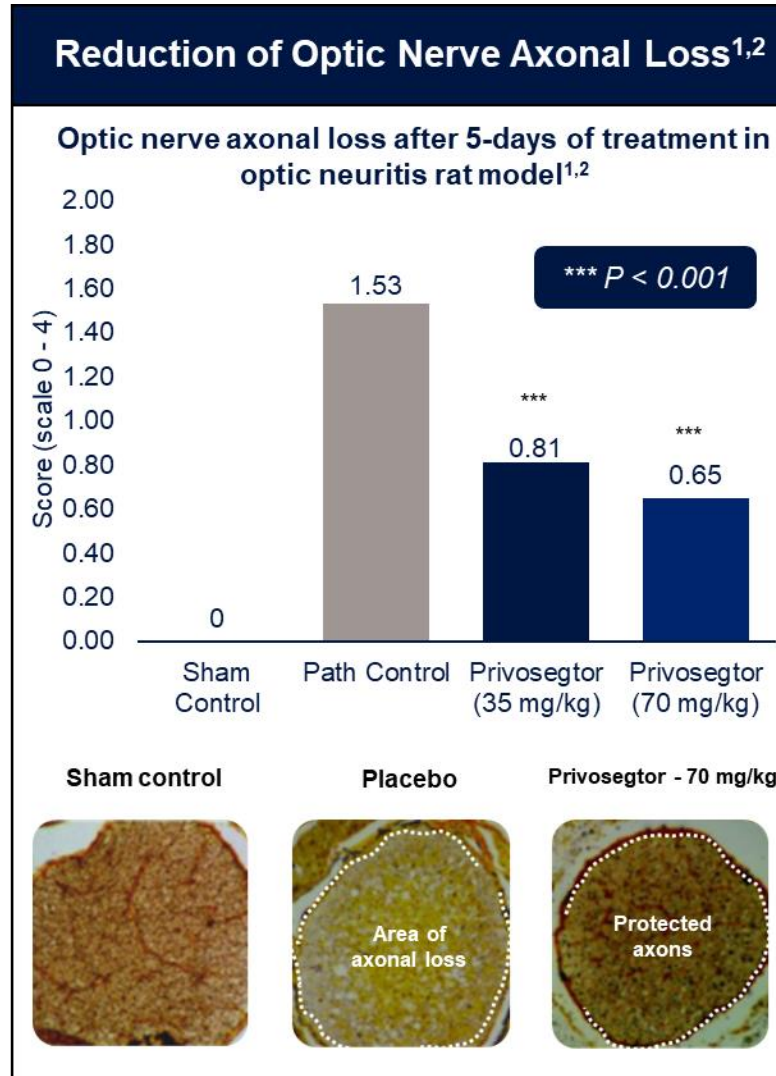
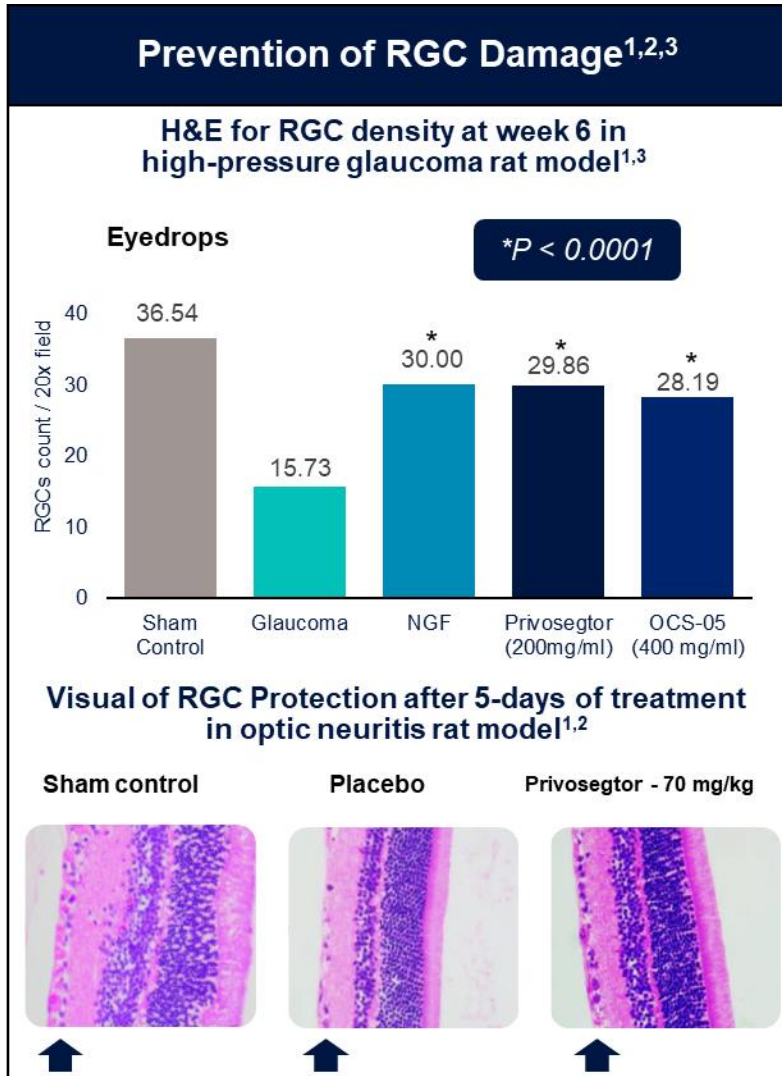


Privosegtor is a Novel Neuroprotective Candidate with Broad Potential for Neuro-axonal Diseases

- Peptoid small molecule that **penetrates blood brain and retinal barriers**
- **Selected by high-throughput screening (HTS) for neuroprotective properties**, confirmed in vivo in glaucoma, MS, and optic neuritis models
- It activates SGK and triggers **multiple beneficial effects on apoptosis, oxidation, and inflammation**
- Received **Breakthrough Therapy Designation** for Optic Neuritis



Preclinical Data Showed Neuroprotection Benefits with Neurons and Axons Preservation/Survival



H&E: hematoxylin and eosin staining; RGC: retinal ganglion cell.

1. Villoslada P, et al. *Neurotherapeutics*. 2019;16(3):808-827
2. Lysolecithin induced demyelinating model in rat (model of acute optic neuritis)- Assessment after 5-days of treatment
3. High pressure Glaucoma rat model of neurodegeneration without inflammation

Phase 2 ACUIITY Trial in Acute Optic Neuritis

Proof-of-concept for neuroprotection

Study Design

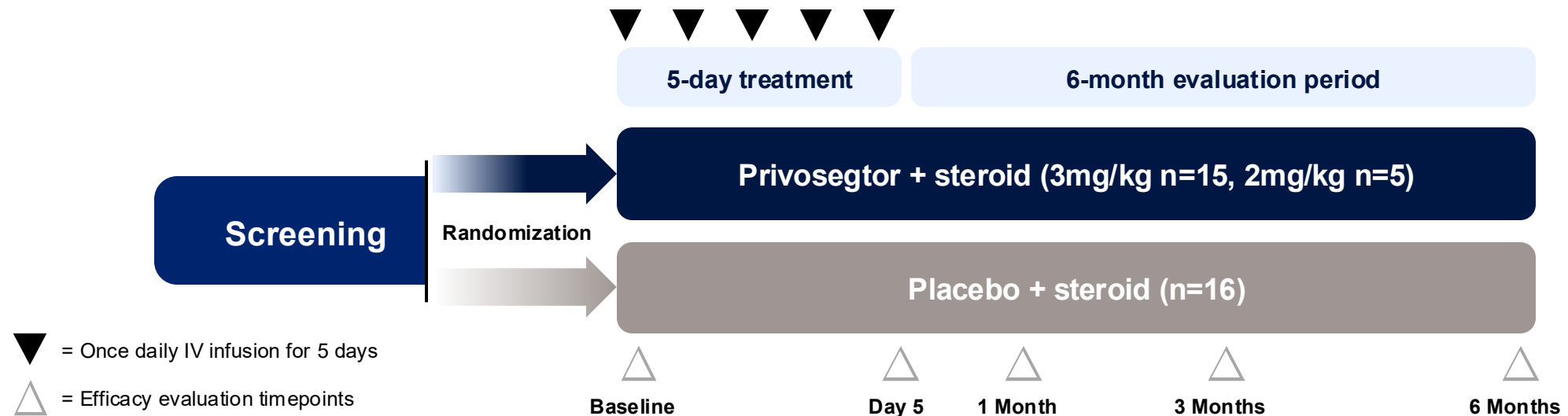
- Randomized, double-masked, placebo-controlled study
- Multi-center, 6-month trial with 36 patients randomized (mITT: 33)
- Once-daily IV infusion of Privosegtor + steroid vs. placebo + steroid for 5 consecutive days

Key endpoints

- Primary endpoint: Safety
- Secondary endpoints:
- Change in Ganglion Cell and Inner Plexiform Layer (GCIPL) thickness as assessed by OCT
 - Change in Retinal Nerve Fiber Layer (RNFL) thickness as assessed by OCT
 - Change in visual function (LCVA)

Study Population

- Patients diagnosed with a unilateral acute optic neuritis
- Onset of visual loss symptoms in the last 12 days before randomization

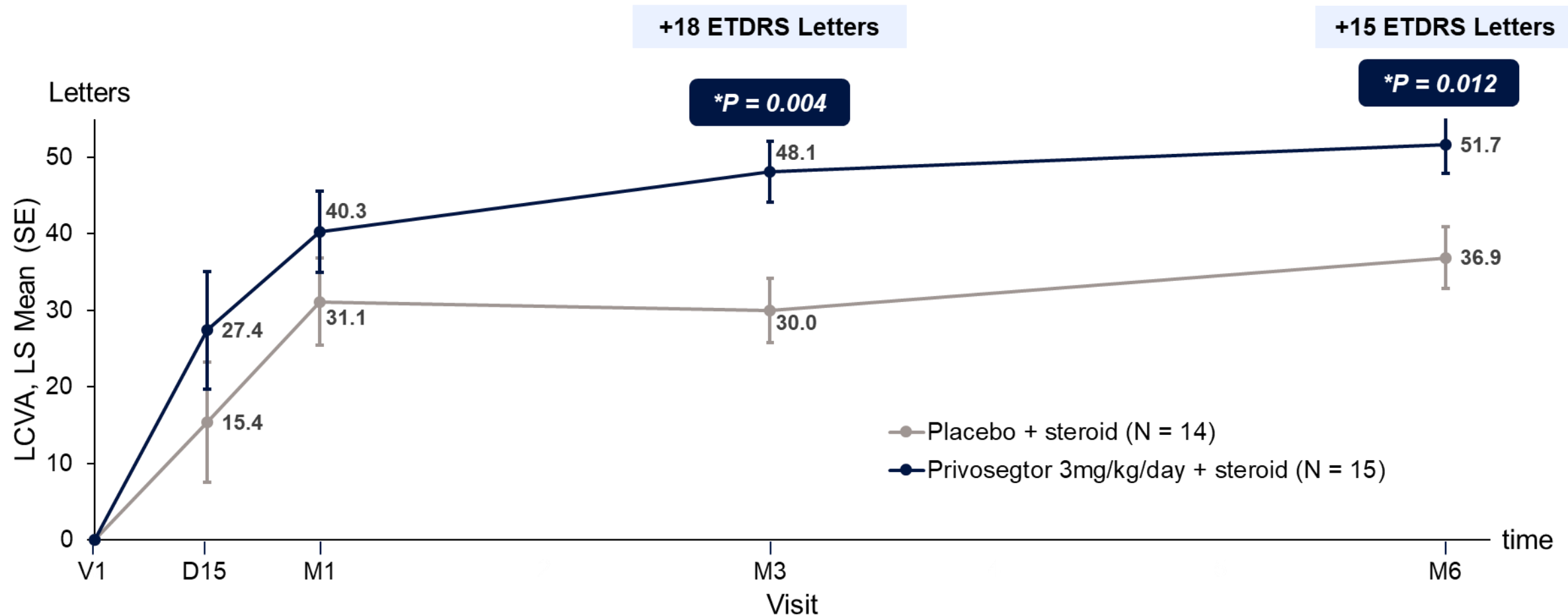


Patient Demographics and Baseline Characteristics

	Privosegtor + steroid 3 mg/kg/day (N = 15)	Placebo + steroid (N = 14)
Age, mean (SD), years	33.7 (9.8)	32.7 (10.3)
Female, n (%)	9 (60.0)	10 (71.4)
GCIPL thickness, mean (SD), μm	89.3 (8.3)	84.3 (13.8)
RNFL thickness, mean (SD), μm	104.6 (13.1)	115.5 (54.1)
HCVA, mean (SD), ETDRS	54.1 (34.5)	42.6 (34.5)
LCVA, mean (SD), ETDRS	19.4 (22.3)	17.8 (24.3)
Visual Field Mean Deviation, mean (SD), dB	-14.1 (11.9)	-14.5 (12.5)
Time since first visual loss symptoms at date of first dose, mean (SD), days	9.5 (2.7)	9.6 (2.5)
Multiple sclerosis at baseline, n (%)	10 (66.7)	9 (64.3)
Disease Modifying Therapies n (%)	10 (66.7)	9 (64.3)

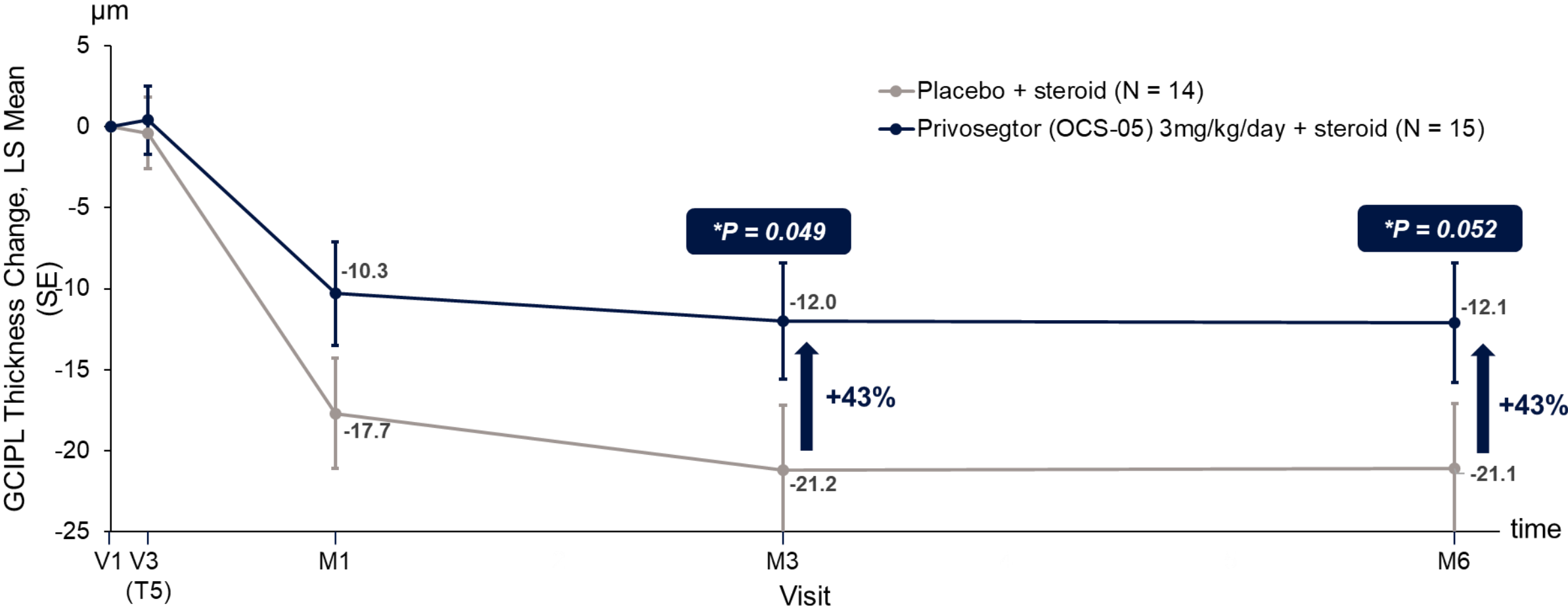
Patients in the Privosegtor 3mg/kg/day Arm Achieved Clinically Meaningful Improvement in Visual Function

2.5% ETDRS LCVA in the Affected Eye: MMRM, LS Mean Change From Baseline, mITT



Patients in the Privosegtor 3mg/kg/day Arm Achieved Less GCIPL Thickness Decrease

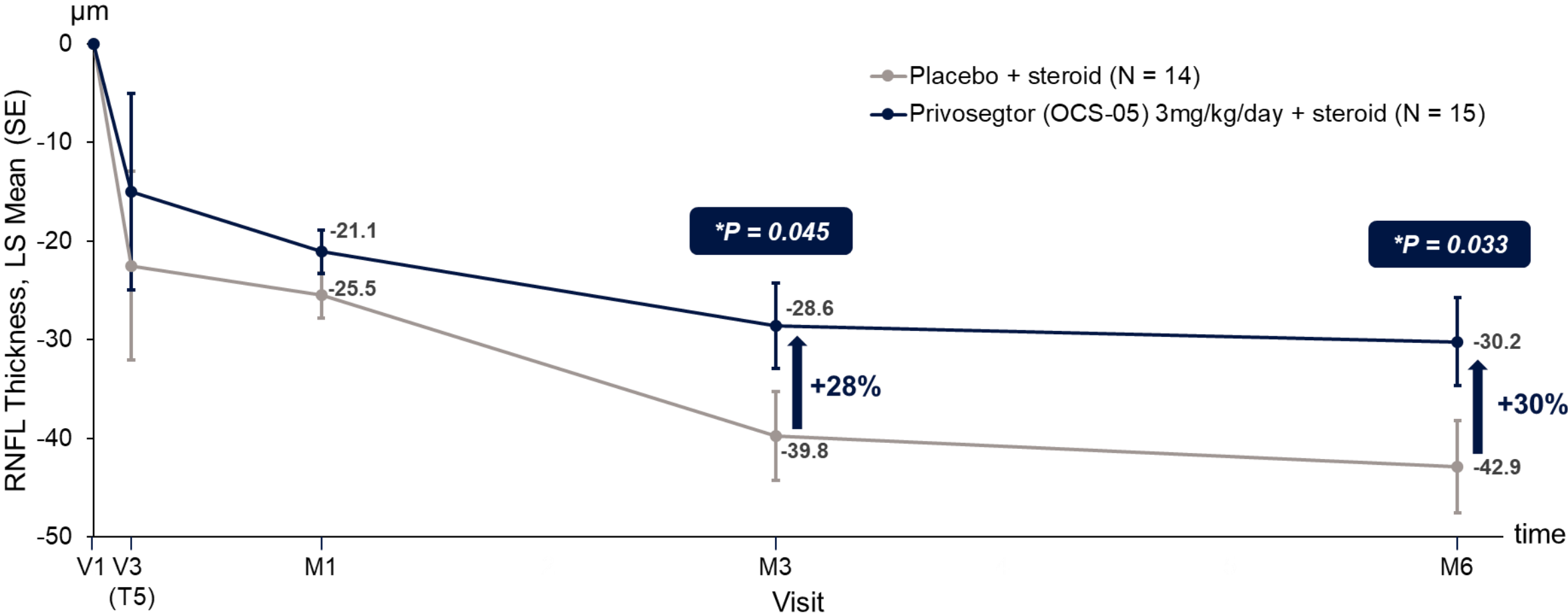
GCIPL Thickness in the Affected Eye: MMRM, LS Mean Change From Baseline, mITT



*Mixed Model for Repeated Measures (MMRM); Least-Squares Mean Change from Baseline: (1-sided directional nominal p-value), mITT population (affected eye)
 GCIPL; ganglion cell plus inner plexiform layer.

Patients in the Privosector 3mg/kg/day Arm Achieved Less RNFL Thickness Decrease

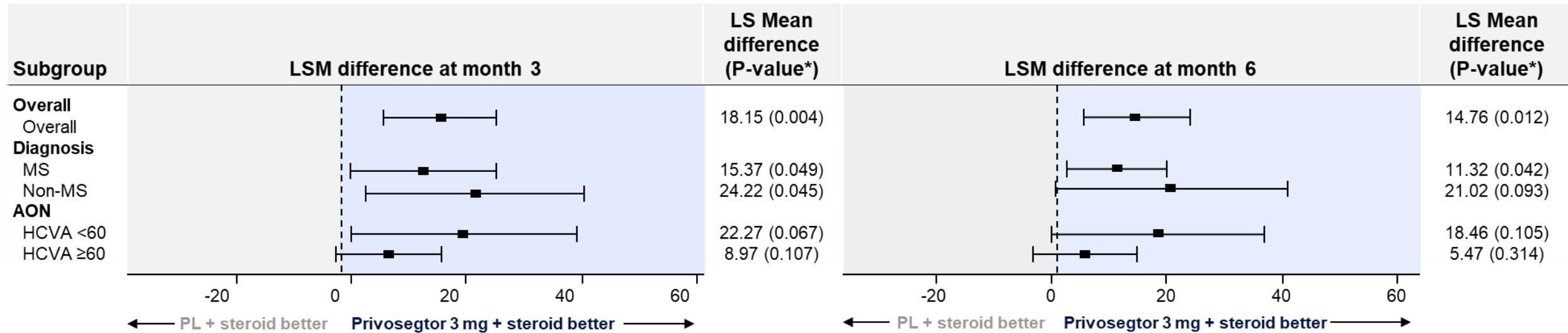
RNFL Thickness in the Affected Eye: MMRM, LS Mean Change from Baseline, mITT



*Mixed Model for Repeated Measures (MMRM); Least-Squares Mean Change from Baseline: (1-sided directional nominal p-value), mITT population (affected eye)
RNFL; retinal nerve fiber layer.

Privosegtor Arm Showed a Robust LCVA Improvement Across all Subgroups and Maintained through Month 6

LCVA letters subgroup analyses of Privosegtor 3mg + steroid vs placebo + steroid



*2-sided nominal p-value based on LSM difference.

AON, acute optic neuritis; HCVA, high-contrast visual activity; LCVA, low-contrast visual acuity; LSM, least square mean; MS, multiple sclerosis; PL, placebo

Safety Profile Reported in ACUIY Phase 2 Trial Showed No AEs Leading to Drug Withdrawal or Study Discontinuation

- No AEs leading to drug withdrawal or study discontinuation
- No drug-related serious adverse events (SAEs)

Event, n (%)	Privosegtor + steroid			Placebo + steroid (N = 14)
	2 mg/kg/day (N = 4)	3 mg/kg/day (N = 15)	Pooled (N = 19)	
At least one TEAE Related to study treatment	4 (100.0%) 4 (100.0%)	12 (80.0%) 6 (40.0%)	16 (84.2%) 10 (52.6%)	14 (100.0%) 6 (42.9%)
At least one grade ≥2 TEAE Related to study drug	2 (50.0%) 0	9 (60.0%) 2 (13.3%)	11 (57.9%) 2 (10.5%)	6 (42.9%) 0
At least one serious TEAE Related to study drug	0 0	1 (6.7%) 0	1 (5.3%) 0	1 (7.1%) 0
At least one SAE leading to death	0	0	0	0
At least one TEAE leading to a dose reduction	0	0	0	0
At least one TEAE leading to a dose interruption	0	0	0	0
At least one TEAE leading to a drug withdrawn	0	0	0	0
At least one TEAE leading to premature discontinuation of the study	0	0	0	0

SAE, serious adverse event; TEAE, treatment emergent adverse event.

Two (2) unrelated SAEs: Hospitalization due to MS relapse (Privosegtor (OCS-05 + steroid) and due to myelitis (placebo + steroid)

ACUITY Phase 2 Results Summary

- 1 Function: Significant improvement in LCVA** with 18 letters difference at month 3
- 2 Structure: less GCIPL and RNFL thickness decrease** preserving axons and RGCs
- 3 Safety: No AEs leading to drug withdrawal or study discontinuation** and no drug related SAEs

Privosegtor showed promising results in protecting vision and structure in AON, which could have benefits in multiple other conditions

Thank you!

**Thank you to all the investigators, study teams, and patients
who contributed to this work**